

**Evidence-based Approaches for the Management of the Proximal Lesion in Adults.  
Summary from the ORCA/EFCD/DGZ Consensus.**

*Rodrigo A. Giacaman, DDS, PhD.*

*Cariology Unit, Department of Oral Rehabilitation*

*University of Talca, Chile*

*[giacaman@utalca.cl](mailto:giacaman@utalca.cl)*

**Conceptualization.** Current conceptualization of caries disease and its consequence; caries lesions, have changed substantially in recent years. Dental caries is currently understood as a chronic, non-communicable disease, caused by frequent exposure to fermentable carbohydrates in the diet, modulated by biological, behavioral, environmental, and psychosocial factors (Machiulskiene et al., 2020). These new conceptions have changed the focus of clinical dentistry from one predominantly restorative to a profession with more decided emphasis on the management of the disease and the preservation of tooth structure throughout the life course (Giacaman, 2017).

Caries disease should be controlled by acting on its causative factors (sugar-rich diets and the dental biofilm), including all the biological, social and cultural elements involved in its onset. On the other hand, clinical management of the caries lesion must be done under the umbrella philosophy of the Minimal Intervention Dentistry, with conservative approaches.

**Caries management Consensus.** Recent changes in caries disease conception and therapeutic management led a panel of experts from the European Organization for Caries Research (ORCA), the European Federation for Conservative Dentistry (EFCD) and the German Federation for Conservative Dentistry (DGZ) to analyze the evidence and achieve consensus recommendations on how to manage the caries process in adults (Schwendicke et al., 2020). Through a meeting in held in Berlin, Germany in 2019 and using an e-Delphi methodology, the experts analyzed the evidence and proposed clinical recommendations.

This article summarizes the main conclusions of the Consensus, particularly those referred to caries management in adults.

**Dental Caries in adults.** In many countries, oral health has been prioritized in children. Although this approach seems reasonable for many reasons, it tends to leave behind the adult population,

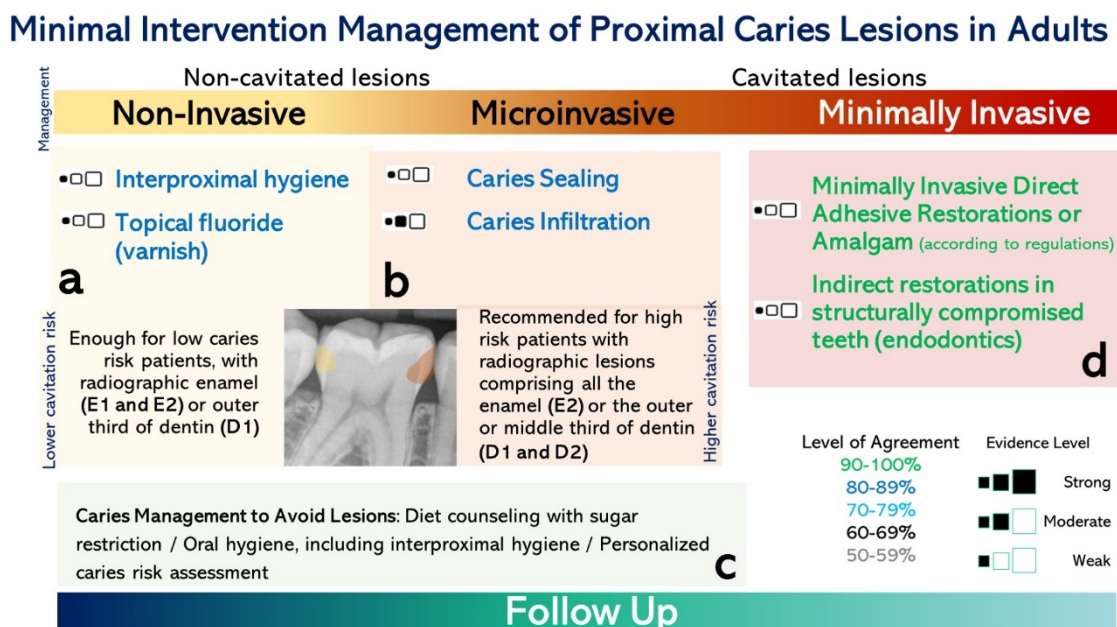
with yet a higher burden of untreated caries. The latter is particularly true in developing countries, where resources are rationalized and directed to the infant population.

Proximal caries lesions and those around restorations or secondary caries lesions continue to be a problem that affects a significant part of the adult population. Once a tooth is restored, a continuous process of replacement of restorations is triggered leading to tooth loss after a number of cycles, phenomenon known as the "restorative cycle" or "death spiral" (Elderton, 1990). Hence, different approaches to manage caries lesions appear necessary in adult patients.

Therapeutic management of proximal and secondary caries lesions occupies an important part of the work of dentists throughout the world and are the most frequent clinical manifestation in adults. Recommendations from the panel of experts are all based on a Minimal Intervention Dentistry approach, with a technically adequate restorative management and, when available, based on the best scientific evidence.

### Intervention of proximal lesions in adults.

Figure 1 summarizes the recommendations for the management of proximal caries lesions in adults, which are divided into:



**Figure 1.** Recommendations for the management of proximal caries lesions in adults using a Minimal Intervention Dentistry approach. Adapted from Echeverría C., et al., Int. J. Inter. Dent 14(1); 32-36, 2021.

**1. Non-invasive strategies (Figure 1a):** These interventions do not involve hard dental tissue removal and are based, for example, on the use of topical fluorides and other chemical agents to control the mineral balance of dental tissue, biofilm control measures and dietary control. Salivary stimulation is also recommended in adults to enhance remineralization.

**2. Microinvasive strategies (Figure 1b):** Microinvasive strategies refer to interventions that involve tissue removal, but at the micron level, usually needing acid conditioning (acid etching). Microinvasive techniques comprise sealants and infiltrating techniques.

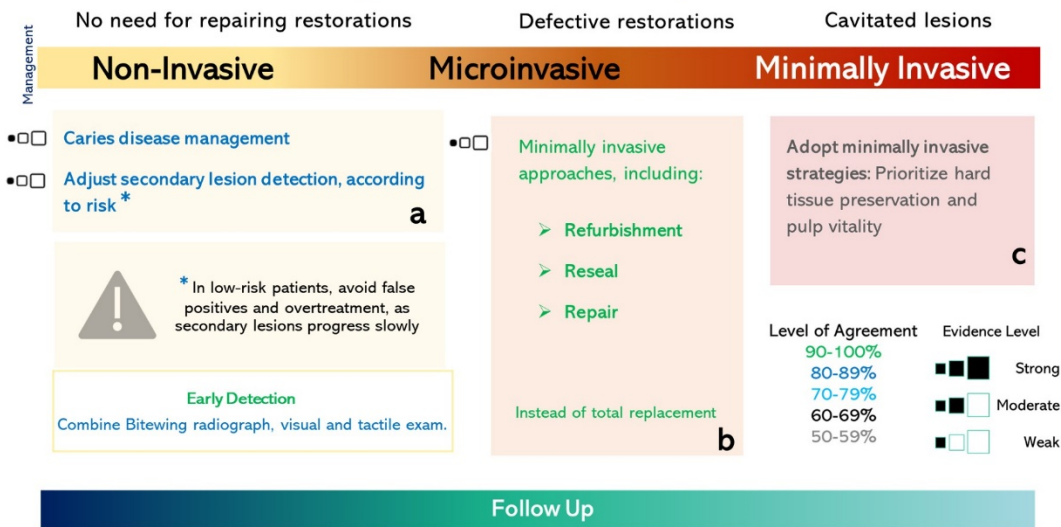
**3. Invasive operative strategies (Figure 1c):** These interventions require necessarily the removal of hard dental tissues affected by the carious process, but they are always driven by the philosophy of Minimal Intervention Dentistry. Thus, once implemented they remove only a limited amount carious dentin, either through manual or rotary instruments, followed by the placement of a restorative biomaterial.

#### **Management of Secondary Caries in Adults.**

The prevalence of secondary lesions increases in high-risk patients, in the cervical margin of restorations and in posterior teeth. The onset of this type of lesion may be the result of an inadequate management of the caries disease and also by the presence of marginal defects, such as overhanging restorations or marginal gaps. Marginal failure creates conditions for dental biofilm stagnation, which changes the local environment favoring mineral loss and lesion progression. Patient- and dentist-related factors, therefore, intervene in the onset of secondary caries, while adhesive strategies and restorative materials appear to play a much less relevant role (Splieth, Kanzow, Wiegand, Schmoedel, & Jablonski-Momeni, 2020).

There is a general agreement on that amalgam restorations are associated with a lower risk of secondary caries (Moraschini, Fai, Alto, & Dos Santos, 2015), and of general failure. Moreover, no relevant differences in clinical success rates have been described among esthetic materials, including composite resins, glass ionomer (GIC) cements, resin-modified GIC (RMGIC), and polyacid (compomer) modified resins (Splieth et al., 2020). Research on this field, however, has limitations derived from several methodological issues, including, short follow-up periods, limited sample sizes and subjects with low caries risk. Therefore, data from these studies should be cautiously interpreted. Beyond the decision on biomaterials, it is important to intervene only when deemed absolutely necessary, doing it with a minimal intervention approach, and managing the underlying disease with non-invasive strategies (Fig. 1a and 2a).

## Minimal Intervention Management of Lesions Adjacent to Restorations



**Figure 2.** Recommendations for the management of secondary caries lesions in adults using IM in Dentistry. Adapted from Echeverría C., et al., *Int. J. Inter. Dent* 14(1); 32-36, 2021.

Early detection of secondary lesions may allow the application of less invasive treatment options such as refurbishment (grinding and polishing) of the surface, resealing, or repairing (Fig. 2b), rather than the complete removal of the restoration and its replacement (Fig. 2c), allowing the preservation of tooth structure and reducing the subsequent risk of treatment complications. When secondary lesions are suspected, a non-invasive strategy should be implemented and regularly monitored (Fig. 2A)

During restoration replacement there is a certain possibility of overtreatment. Given the slow progression of lesions, it is advisable to reassess during follow-ups and not to intervene (Schwendicke, Brouwer, Paris, & Stolpe, 2016). On the other hand, despite the obvious advantages of the minimal intervention approach such as reduction of removed dental tissue, reduction of pulp damage, and prolonged tooth survival, careful case selection is mandatory.

### Conclusions.

One of the most relevant challenges in providing oral care for the adult patient is to avoid triggering the restoration cycle, which occurs when an excessively restorative approach is taken. The goal in caries management should be to control the disease and halt lesion progression, ultimately ensuring tooth and function preservation throughout the life course, especially in a context of an aging world with longer life expectancies.

A minimal intervention strategy to manage caries in adults is strongly advised. Non-invasive, microinvasive and minimally invasive techniques for caries lesion management can be implemented and are preferred, according to the lesion severity and activity and to a personalized caries risk assessment, including biological and social factors. Secondary caries lesions and defective restorations should be carefully assessed before intervening to make sure no other option is suitable.

The ORCA/EFCD/DGZ consensus offers general, evidence-based guidelines to for clinicians and recommendations from global experts on how to approach the caries process in adults and can contribute towards the decision-making process.

## References

- Elderton, R. J. (1990). Clinical studies concerning re-restoration of teeth. *Adv Dent Res*, 4, 4-9. doi:10.1177/08959374900040010701
- Echeverría C., Fernández CE., Valdés S., Santamaría RM., Splieth C., Paris S., Schwendicke F., Giacaman RA. (2021). How to Intervene the Caries Process in Adults? Adaptation of the ORCA/EFCD/DGZ Consensus. *Int. J. Inter. Dent* Vol. 14(1); 32-36.
- Giacaman, R. (2017). Preserving healthy teeth throughout the life cycle, the biological asset. *J Oral Res*, 6(4), 80-81.
- Machiulskiene, V., Campus, G., Carvalho, J. C., Dige, I., Ekstrand, K. R., Jablonski-Momeni, A., Nyvad, B. (2020). Terminology of Dental Caries and Dental Caries Management: Consensus Report of a Workshop Organized by ORCA and Cariology Research Group of IADR. *Caries Res*, 54(1), 7-14. doi:10.1159/000503309
- Moraschini, V., Fai, C. K., Alto, R. M., & Dos Santos, G. O. (2015). Amalgam and resin composite longevity of posterior restorations: A systematic review and meta-analysis. *J Dent*, 43(9), 1043-1050. doi:10.1016/j.jdent.2015.06.005
- Schwendicke, F., Brouwer, F., Paris, S., & Stolpe, M. (2016). Detecting Proximal Secondary Caries Lesions: A Cost-effectiveness Analysis. *J Dent Res*, 95(2), 152-159. doi:10.1177/0022034515617937
- Schwendicke, F., Splieth, C. H., Bottenberg, P., Breschi, L., Campus, G., Doméjean, S., Banerjee, A. Ekstrand K, Giacaman RA, Haak R, Hannig M, Hickel R, Juric H, Lussi A, Machiulskiene V, Manton D, Jablonski-Momeni A, Opdam N, Paris S, Santamaria R, Tassery H, Zandona A, Zero D, Zimmer S, Banerjee A. (2020). How to intervene in the caries process in adults: proximal and secondary caries? An EFCD-ORCA-DGZ expert Delphi consensus statement. *Clin Oral Investig*, 24(9), 3315-3321. doi:10.1007/s00784-020-03431-0
- Splieth, C. H., Kanzow, P., Wiegand, A., Schmoeckel, J., & Jablonski-Momeni, A. (2020). How to intervene in the caries process: proximal caries in adolescents and adults-a systematic review and meta-analysis. *Clin Oral Investig*, 24(5), 1623-1636. doi:10.1007/s00784-020-03201-y